

---

# Percutaneous Vertebroplasty

Mubin Syed, M.D., Solomon Jan, M.D., Neel A. Patel, M.D., Azim Shaikh, M.D.

Department of Radiology, Mercy Medical Center, Springfield, OH, USA

**Abstract:** We introduce a relatively new procedure that is gaining acceptance as a therapeutic modality for patients suffering from vertebral body compression fractures. This procedure, percutaneous vertebroplasty, can be used to help treat vertebral body fractures of those suffering from osteoporosis, bone metastasis, or direct trauma when medical therapy has failed. Our own research, as well as current literature, suggests that this procedure has a very high success rate, and is safe with a complication rate of 1-3%. Our goal is to educate physicians of this procedure so they may offer an alternative treatment for those patients who are suffering from vertebral body compression fractures.

**Key Words:** Percutaneous Vertebroplasty, Vertebral Body Compression Fracture, Osteoporosis

## Introduction

The Osteoporosis Foundation reports that 10 million Americans suffer from osteoporosis. In this population, 1.5 million fractures occur annually with 700,000 being vertebral body fractures.<sup>1</sup> The number of hospital admissions that occur due to vertebral body fractures is 150,000 annually.<sup>2</sup> It has been estimated that 50% of all women and 25% of all men over age 50 will have an osteoporosis-related fracture in their lifetime<sup>1</sup>. Furthermore, for those patients who have had a vertebral fracture, the risk of subsequent vertebral fracture is five-fold, with the one-year risk of a second fracture after an initial fracture being 20%.<sup>3</sup> The purpose of this review article is to introduce percutaneous vertebroplasty which is becoming a common treatment modality for the clinical manifestations that result from vertebral body compression fractures.

Medicare describes percutaneous vertebroplasty as a “therapeutic procedure that interventional radiologists perform by injecting biomaterial (methylmethacrylate) into an affected vertebra for pain relief and fracture stabilization”.<sup>4</sup> This relatively new procedure was first described in Europe in 1987.<sup>5</sup> It was first performed in the U.S. at the University of Virginia in 1994 and described later in a paper in 1997.<sup>6</sup> See Table 1 and Table 2 for indications and absolute and relative contraindications.

## Clinical Features and Diagnosis

Clinical manifestations that can occur secondary to vertebral fractures include back pain, difficulty standing and walking, and the inability to perform activities of daily living. Occasionally, patients may present with chest pain for thoracic fractures, or abdominal pain for lumbar or lower vertebral fractures. Chronic symptoms include loss of height, increase in kyphosis, difficulty in balance and lower lung volumes.<sup>3</sup> For each thoracic vertebral compression fracture there is an average 9% loss of forced vital capacity.<sup>7</sup> The calculated risk of increased mortality is 23-34% for a kyphosis due to vertebral compression fracture.<sup>8</sup> Our goal with vertebroplasty is to increase the patients’ quality of life by alleviating the intractable back pain associated with these fractures and in essence decrease mortality by improving lung function and mobility.

Initially, primary care physicians may be the first to diagnose compression fractures, which characteristically have an acute presentation, often but not necessarily related to trauma or other precipitating factors. The pain is typically very severe and sharp in nature, worsened by weight bearing or sometimes by any type of movement. The pain may become intractable and require hospital admission.

Usually primary care doctors refer patients after a trial of conservative therapy has been completed. Once the complete history is obtained, physical examination is performed including focal point tenderness. Radiologic imaging is then required. An MRI is more specific, but in cases where the patient is

---

Presented at the International Institute of Islamic Medicine (IIIM) and Islamic Medical Association of North America (IMANA) Meeting, January 2005, Dubai, United Arab Emirates.



unable to have an MRI, CT scan is appropriate. For those patients whose fracture site cannot be determined, a bone scan is helpful. The combination of focal point tenderness and an MRI with or without bone scan is highly useful in locating the specific vertebra that may be affected. The MRI gives us certain pieces of information that is crucial in determining if the patient is a good candidate for vertebroplasty. Specifically one must look for signs of marrow edema, retro-pulsed fragments, and nerve root compression. Marrow edema is present on MRI when there is an acute vertebral body fracture. Many candidates have mild to severe retropulsion on MRI. However, as long as there are no neurological deficits or radiculopathy, they could be candidates for vertebroplasty.

### **Technique and Subsequent Management**

Upon completion of the initial workup, appropriate candidates can undergo vertebroplasty. Vertebroplasty is usually performed with high quality C-arm fluoroscopy. Fluoroscopy is done to locate the specific site of the vertebral body compression and for guidance in needle placement. (See Figure 1) The procedure can be done using local anesthesia, but it is frequently performed using conscious sedation. Rarely is general anesthesia given. An 11-gauge or 13-gauge needle (trocar) is then advanced into the vertebral body using either a transpedicular or parapedicular approach. (See Figure 2) Upon proper placement of the trocar, a mixture of antibiotics and bone cement consisting of polymethylmethacrylate is then injected, using a cement delivery system (Stryker-Howmedica Osteonics, Kalamazoo, MI) into the vertebral body where it diffuses throughout the intertrabecular marrow space. (See Figure 3 and Figure 4) This cement then hardens, forming a stable splint, reinforcing the vertebra and alleviating the pain. The volume of cement that is injected varies between 1 ml and 14 mls. This depends on the size of the vertebra and the operators' technique. Lower volumes of cement are more optimal as it decreases the chances of leakage.<sup>9</sup> Common locations for leaks are the paravertebral vessels, the intravertebral disks, and the epidural space, although these are usually asymptomatic. This procedure can then be repeated using the other pedicle if inadequate filling of the vertebra was achieved. The goal is not to fill the entire vertebral marrow space but inject so that the cement is confined to the anterior two thirds or

three quarters of the vertebral body.<sup>10</sup>

Once the procedure is complete, patients are observed for 2 hours and then discharged. Patients are told to slowly increase their activity over a one-month period. Our follow up usually consists of telephone calls at 1 day, 1 week, 2 weeks, 1 month and 3 months after discharge. On each follow up phone call, pain levels are assessed. After 3 months, patients are encouraged to call if there is any severe reoccurrence of pain. Rarely do patients need pain medications, but in some instances pain is not completely relieved. Frequently, the patients have been on some type of pain medication prior to the procedure. In the patient population that only receives partial relief of pain from vertebroplasty, we recommend they start a smaller dose of the pain medication they were previously taking. Also of note, a common complaint is muscle soreness at the point of needle insertion which usually resolves within one week.

### **Results and Discussion**

The incidence of complications has been reported to be between 1-3 percent. Potential complications include hemorrhage, infection, pulmonary embolism, local trauma to nerve roots, spinal cord, lung, or fracture of pedicle.<sup>10</sup> 1-2 percent of patients have transient episodes of recurrent pain.<sup>10</sup> Due to the occurrence of new fractures, some patients receive multiple vertebroplasties before they are relieved of their back pain.

In our experience of 542 patients with 878 patient encounters and 1273 levels treated between July 1999 and August 2004, 84% of patients obtained significant relief (53.4% total relief, 30.6 % partial relief, while 16% of the patients experienced no relief).<sup>11</sup> Of these patients, one patient died as a result of fat embolism.<sup>12</sup> One patient sustained rib fractures with no long-term sequelae during two separate sessions. One patient with treated osteomyelitis (6 weeks of intravenous antibiotics and negative vertebral body biopsy) developed recurrent infection. This patient however was requested to have vertebroplasty by the referring neurosurgeon who was hoping to avoid a corpectomy (removal of vertebral body). Another patient developed a radiculopathy, despite negative evidence of any cement leak via MRI/CT. One patient

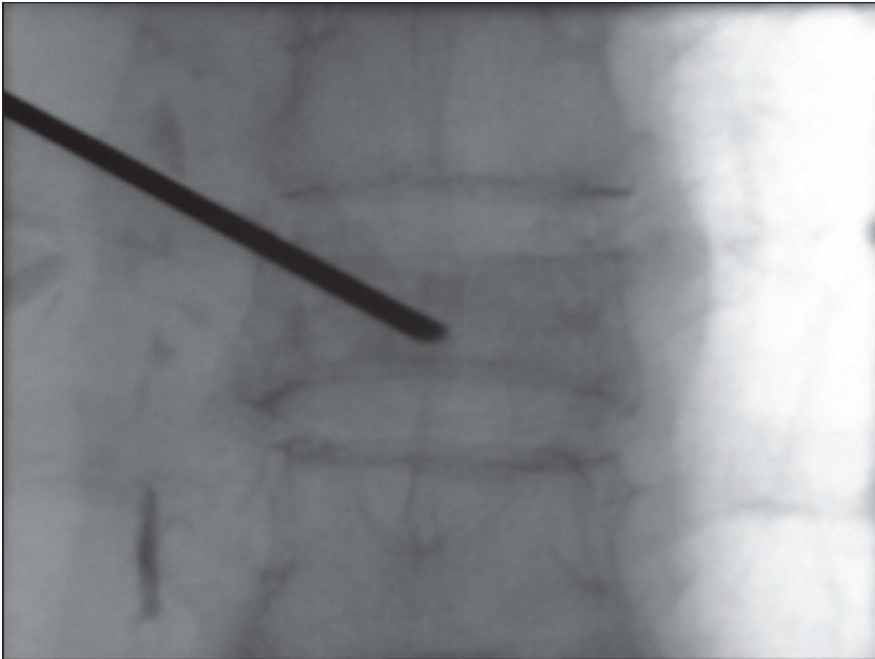


Figure 1: This view identifies pedicle boundaries in AP view prior to needle insertion.

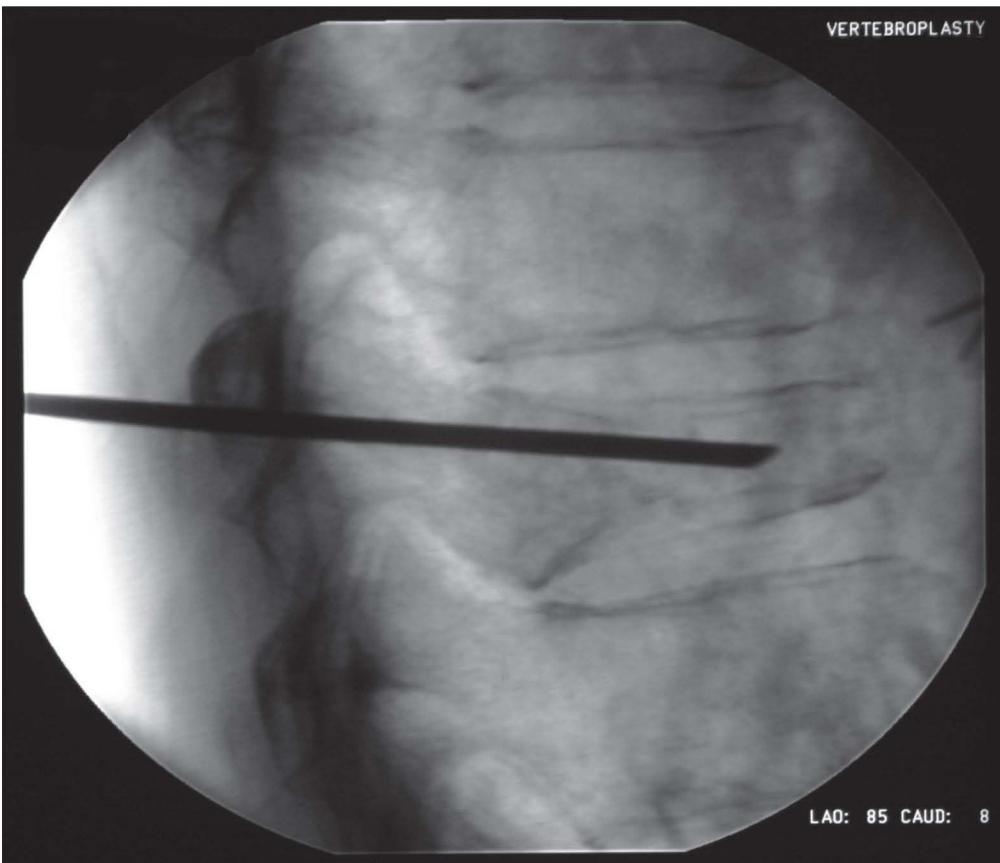


Figure 2: Lateral fluoroscopic view showing needle advancement in vertebral body.

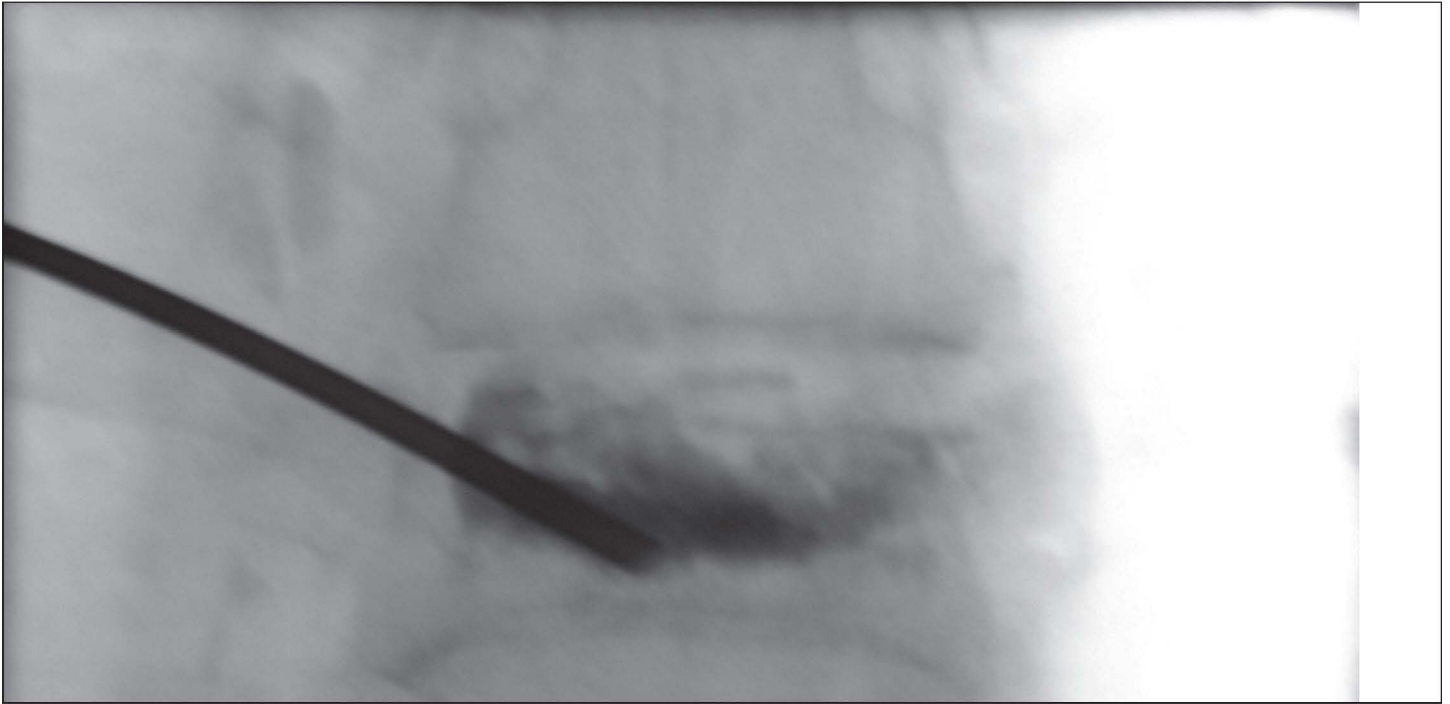

Figure 3: AP view after filling of a vertebra with cement and antibiotic mixture

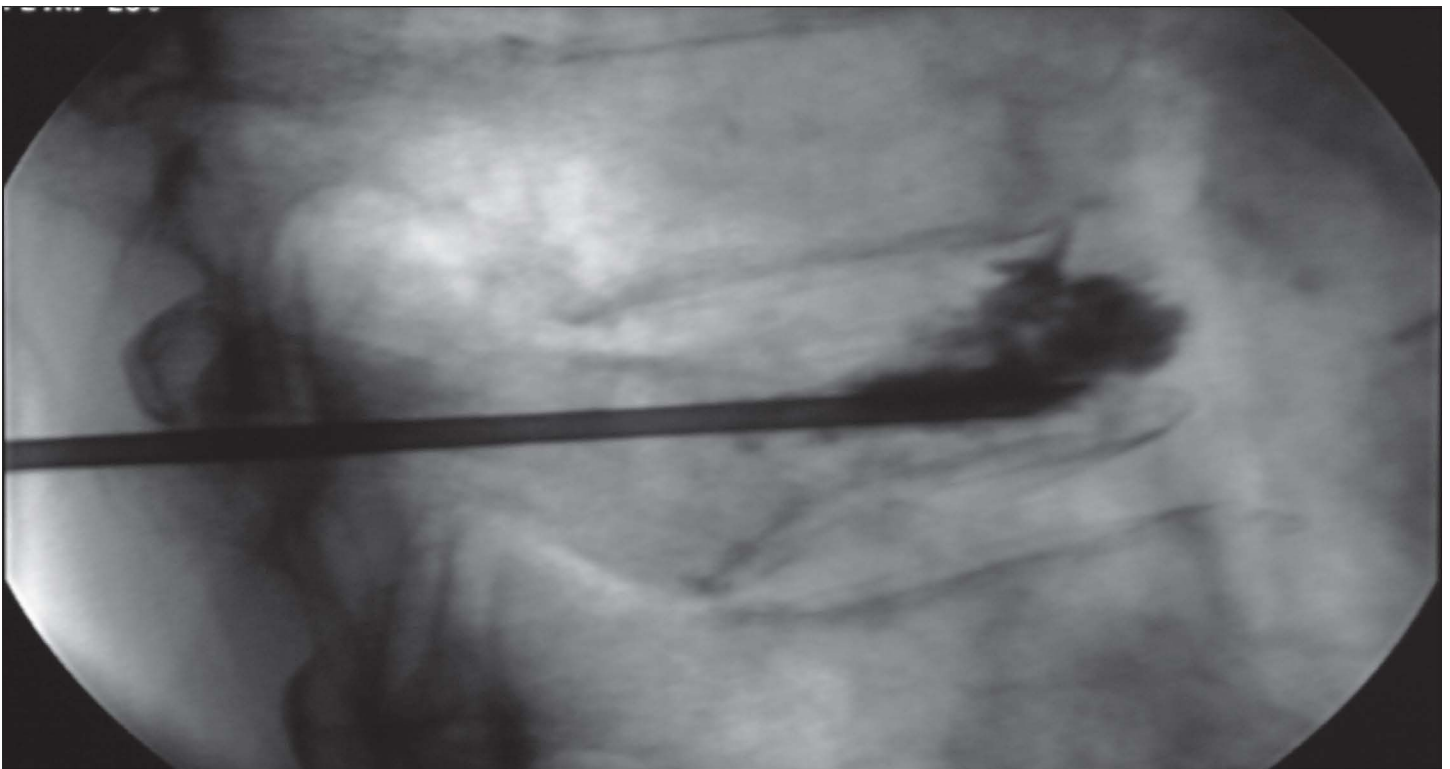


Figure 4: Lateral view showing filling of a vertebra with cement mixture



**Table 1. Indications for Percutaneous Vertebroplasty**

- 1) Painful osteoporotic fractures refractory to medical therapy
- 2) Unstable painful metastasis and multiple myelomas
- 3) Painful vertebral hemangiomas
- 4) Painful fracture associated with osteonecrosis
- 5) Reinforcement of weakened vertebra prior to surgical stabilization

**Table 2. Contraindications for Percutaneous Vertebroplasty**

**Absolute Contraindications**

- 1) Responsive or healed osteoporotic fracture
- 2) Presence of untreated coagulopathy
- 3) Prophylaxis for osteopenic patients
- 4) Discitis/osteomyelitis or sepsis

**Relative Contraindications**

- 1) Significant compromise of the spinal canal
- 2) Back pain or known fracture for greater than one year
- 3) Vertebral body collapse of 90% or greater
- 4) Tumor extension into epidural space<sup>2,9</sup>

developed worsening of radiculopathy, which responded to epidural steroids. Again, in this patient, there was no evidence of cement leakage. No other complications such as bleeding, infection, paralysis or other neurological sequelae were noted.

A study showed a 90 percent success rate with vertebroplasty on 231 patients who suffered from osteoporotic vertebral fractures and an 80 percent success rate in painful or unstable neoplastic lesions.<sup>13</sup> Another study has shown that 90 percent of patients (29 patients with 47 fractures) with age-related or steroid induced osteoporosis had pain relief and improved mobility 24 hours post-vertebroplasty.<sup>14</sup> A third study reports 97 percent of patients who were treated for painful metastasis and multiple myeloma received complete or partial relief (37 patients).<sup>15</sup> These studies do show a high success rate, but the population of patients used in their studies was relatively low.

In conclusion, percutaneous methacrylate ver-

tebroplasty is an extremely efficacious procedure that can have a tremendous impact on the quality of life in patients with severe debilitating pain due to vertebral body fractures or tumors. The procedure is very safe due to its minimally invasive nature.

**References**

1. National Osteoporosis Foundation [homepage on the Internet]. Washington, D.C.: The Association; c2005 [cited 2002 Aug 29], Fast facts on osteoporosis. Available from <http://www.nof.org/osteoporosis/diseasefacts.htm>.
2. Predey TA, Sewall LE, Smith SJ. Percutaneous vertebroplasty: new treatment for vertebral compression fractures. *Am Fam Physician* 2002 Aug 15; 66(4): 611-5.
3. Papaioannou A, Watts NB, Kendler DL, et al. Diagnosis and management of vertebral fractures in elderly adults. *Am J Med.* 2002 Aug 15;113(3):220-8.
4. Medicare Part B Local Medicare Review Policy Description. Available at: <http://www.floridamedicare.com> (accessed 1/16/03)
5. Galibert P, Deramond H, Rosat P, Le Gars D [Preliminary note on the treatment of vertebral angioma by percutaneous acrylic vertebroplasty] *Neurochirurgie* 1987;33(2):166-8.
6. Jensen ME, Evans AJ, Mathis JM, et al. Percutaneous polymethylmethacrylate vertebroplasty in the treatment of osteoporotic vertebral body compression fractures: technical aspects. *Am J Neuroradiol* 1997 Nov-Dec;18(10):1897-904.
7. Schliach C, Minne HW, Buckner T, et al. Reduced pulmonary function in patients with spinal osteoporotic fractures. *Osteoporosis Int.* 1998;8(3):261-7.
8. Kado DM, Browner WS, Palermo L, et al. Vertebral fractures and mortality in older women: a prospective study. *Study of Osteoporotic Fractures Research Group.* *Arch Intern Med.* 1999 Jun 14; 159(11):1215-20.
9. Lin E, Ekholm S, Hiwatashi A, et al. Vertebroplasty: cement leakage into the disc increases the risk of new fracture of adjacent vertebral body. *Am J Neuroradiol.* 2004 Feb;25(2):175-80.
10. Zoarski GH, Stallmeyer MJ, Obuchowski A. Percutaneous vertebroplasty: A to Z. *Tech Vasc Interv Radiol.* 2002 Dec;5(4):223-38.
11. Syed M., Patel N, Jan S et al. New symptomatic vertebral compression fractures within a year fol-

---

lowing vertebroplasty in osteoporotic women. Am J Neuroradiol 2005 Jun-Jul;26(6):1601-4.

12. Syed M, Jan S, Patel N et al. Fatal fat embolism following vertebroplasty: identification of the high risk patient. Am J Neuroradiol 2005 (in press)

13. Deramond H, Depriester C, Galibert P, Le Gars D. Percutaneous vertebroplasty with polymethylmethacrylate. Technique, indications, and results. Radiol Clin North Am 1998 May;36(3):533-46.

14. Jensen ME, Evans AJ, Mathis JM, et al. Percutaneous polymethylmethacrylate vertebroplasty in the treatment of osteoporotic vertebral body compression fractures: technical aspects. Am J

Neuroradiol. 1997 Nov-Dec;18(10):1897-904.

15. Cotten A, Dewatre F, Cortet B et al. Percutaneous vertebroplasty for osteolytic metastases and myeloma: effects of the percentage of lesion filling and the leakage of methylmethacrylate at clinical follow-up. Radiology. 1996 Aug;200(2):525-30.