

## History of Medicine

### Treatment of Anorectal Diseases by al-Rāzī

Adil H. AL-Humadi, MD, FACS<sup>1</sup>, Sadiq Al-Samarrai, MD<sup>2</sup>

<sup>1</sup>Clinical Assistant Professor of Surgery, Division of Colorectal Surgery

<sup>2</sup>Clinical Assistant Professor of Psychiatry, Department of Psychiatry

State University of New York at Buffalo

Buffalo, New York

#### Abstract:

This paper examines the writings of Abū Bakr Muḥammad ibn Zakariyyā al-Rāzī (d. 313 AH/925 CE), known to Europeans as Rhazes, regarding anorectal disease, including hemorrhoids, incontinence, fissures, rectal prolapse, ulcers, itching, abscesses, solid swelling, and fistulas. His writings reveal that the surgical treatment of anorectal disease was theoretically sound. Anorectal disease was managed with utmost care and diligence.

**Key words:** Anorectal disease, history of medicine, Islamic medicine, Rhazes

#### Introduction

Abū Bakr Muḥammad ibn Zakariyyā al-Rāzī (died 313 AH/925 CE), known to Europeans as Rhazes, earned a great reputation as an eminent surgeon of his time. His students compiled his notes into a book entitled *al-Ḥāwī fī al-ṭibb* (The Comprehensive Book on Medicine).<sup>1</sup> *Al-Ḥāwī* was repeatedly mentioned centuries later in the texts written by Ibn Sīnā (died 428 AH/1037 CE)<sup>2</sup> and ibn al-Quff al-Karakī (died 685 AH/1286 CE).<sup>3</sup> It also reached Europe. According to the U.S. National Library of Medicine:

It was translated into Latin in 1279 under the title *Continens* by Faraj ben Salīm, a physician of Sicilian-Jewish origin employed by Charles of Anjou to translate medical works, and it had considerable influence in Europe as well as in the Islamic world.<sup>4</sup>

This paper will summarize al-Rāzī's writings on anorectal disease to demonstrate that its surgical treatment was well-recognized and treated with utmost care and diligence. Al-Rāzī's text deals with

the treatment of hemorrhoids, incontinence, fissures, rectal prolapse, ulcers, itching, abscesses, solid swelling, and fistulas.

#### Sources and Methodology

The primary source used for this paper is *Kitāb al-ḥāwī fī al-ṭibb*. *Al-Ḥāwī*, in its modern, incomplete printed version, fills 23 volumes.<sup>1,5</sup> Alī ibn al-Abbās al-Majūsī wrote that its enormous size precluded its duplication and circulation and criticized its lack of organization. According to Emilie Savage-Smith, ibn al-Amīd, the *wazīr* (minister) of the Buwayhid ruler Rukn al-Dawla, arranged in 327 AH/939 CE for al-Rāzī's pupils after his death to compile his notes into the volume that came to be *al-Ḥāwī*.<sup>5</sup> Savage-Smith wrote:

The *Hawī* is an extremely important source for knowledge of Greek, Indian, and early Arabic writings now lost, for al-Rāzī was meticulous about crediting his sources. Moreover the clinical cases, while not unique, are the most numerous and varied in the Islamic medieval medical literature. The material comprising the *Hawī* is arranged under the headings of different diseases, with separate sections on pharmacological topics.<sup>5</sup>

Correspondence should be directed to Dr. Adil al-Humadi at [adilalhumadi@hotmail.com](mailto:adilalhumadi@hotmail.com).

Professor Pormann discussed the use of al-Rāzī as a source for understanding classical authors whose works are no longer extant.<sup>6</sup>

Another source to supplement our understanding of al-Rāzī's knowledge of the treatment of anorectal disease is al-Rāzī's *al-Manṣūrī fī al-ṭibb*.<sup>7</sup>

It is a challenge for the modern Arabic-speaking physician to understand the terms in these texts. It is especially difficult to identify the substances these ancient physicians used. In addition, translation of these texts is a balance between the literal and the technical. Using modern medical terminology in translation facilitates understanding, but there is a danger of attributing a modern understanding based on contemporary medical knowledge to a historical figure. The translations in this article strike a balance, and the Arabic texts are frequently reproduced to facilitate review of the translations. Bracketed numbers indicate page numbers from *al-Ḥāwī*. Bracketed question marks in a translation indicate doubt in the accuracy of the translation. In some sections, we comment on al-Rāzī's writings to clarify them to the reader.

### Diseases of the Anorectal Region

Al-Rāzī begins by noting that diseases of the anorectal region are difficult to treat:

علل المقعدة عسرة البرء لأن الثفل يمر بها ولأنها  
كثيرة الحس و لأن الأدوية لا يمكن أن توضع  
عليها و تحتاج إلى القابضة و هي لا تحملها  
لنكايته إياها بقبضها و هي بشدة حسها تألم ألماً  
شديداً

Diseases of the anus resist healing because fecal matter passes through it, it is extremely sensitive, it is difficult to keep medication on it, it requires astringent constricting drugs, and it produces intense pain due to its sensitivity. [29]

### Hemorrhoids

#### Diagnosis

This passage describes partly what physicians do today to differentiate between hemorrhoids and ulcer alterations.

من شكاً إليك من العامة بواسير فمره أن يُريك  
اختلافه فإن كان كثيراً تكون به قروح في أمعائه و  
قد شكاً إلي ذلك رجل و لما بحثت عن أمره كانت  
به قرحة مزمنة فحقنته بحقن الرازيانج فبراً

Whenever a common person complains of hemorrhoids, order him to show you his stool. If it is great in quantity, he has intestinal ulceration. A man once complained of hemorrhoids to me. When I examined him, I found he had a chronic ulcer. I gave him fenel enema, and he became well.[52]

Al-Rāzī thought that hemorrhoids swelled in the anal area due to the engorgement of the rectal vessel from the backup pressure of the dark (venous) blood from the liver.

ليس يمكن أن تحدث البواسير دون أن تنتفخ أفواه  
العروق إلى المقعدة بسبب كثرة الدم و غلظه لدفع  
الكبد إليها الدم العكر السوداوي

Hemorrhoids do not happen without the expansion of the venous ends of the blood vessels in the anus due to the increase in blood and its viscosity because of the liver pushing darkened, impure blood to the anus.[32]

In contemporary medicine, cirrhosis of the liver is, as al-Rāzī described, one of the causes of hemorrhoids. Other causes of hemorrhoids that al-Rāzī did not mention include heavy lifting, constipation, and pregnancy.

Al-Rāzī accurately describes anal muscle function.

حركة العضل [المقالة] الأولى منها العضلة التي على  
تجويف المقعدة تحرك نفسها بأن تنضم و هي بمتزلة  
الأكياس التي تفتح و تشرح و قال في المقالة الثانية  
من هذا الكتاب كثيراً ما يسرف في قطع العضلة  
التي على المقعدة فتخرج الفضول بلا إرادة

[Regarding] the function of the [anal sphincter] muscle, [according to] The First [Treatise]: The external sphincter muscle of the anal canal moves itself by contracting. It is like a sac which opens and expands. He said in the Second Treatise of that book: Frequently, when the [external sphincter] muscle over the anus is excessively cut [in surgery], bowel incontinence results.

منافع الأعضاء: العضل الذي يضبط فم المعى  
المستقيم و يمنع الثفل أن يخرج إلا بالإرادة هو  
موضوع بالعرض لي إذا كان هذا هكذا فلا بد في  
خزم البواسير من أن ينقطع ليف هذا العضل  
بالعرض و لسنا نرا أنه يلزم كل خزم بطلان فعل  
هذا العضل فبقي أن تكون ربما كانت البواسير  
قريبة من فضاء المقعدة و هذا لا ينقطع فيه كل  
ليف العضلة و لكن بعضه و ربما كان بعيداً حتى  
أنه يكون من خلف العضل كله و هذا إذا خزم  
انقطع ليف العضلة أجمع بالعرض في موضع القطع  
فيجب أن يكون توكيك و إقدامك بحسبه

[Galen in] *Manāfi` al-a`dā`* [wrote]: The muscle which controls the opening of the anus and prevents bowel movements from emerging without control is transverse [the external sphincter muscle]. I say: Were this true, then it would be necessary when ligating hemorrhoids for the fiber of the [external sphincter] muscle to be cut transversely. I do not believe that every time you ligate a hemorrhoid the sphincter muscle is damaged. Sometimes, the hemorrhoid is close to the lumen of the anus, and, in this case, only part of the fiber of the muscle will be cut. Sometimes, the hemorrhoid is deeper [in the anal area], even to the extent that it is behind the entire muscle. In this case, if the hemorrhoid is excised, the muscle fiber is cut

entirely across its circumference at the point of excision. Therefore, your [surgical] restraint and aggressiveness must take this into account.[76]

Al-Rāzī observed that the muscle of the anal canal is transverse (circular) and contracts and closes the anus. It lifts the anal canal upward to protect the pelvic organ and prevent prolapse. In appearance, it is like a sac that inflates and deflates. He concluded that if the tissue muscle is cut deeply or extensively, it will lead to fecal incontinence.[32-3, 76]

#### Symptoms

Hippocrates in his book "Epidemics" said that if blood is emerging from the hemorrhoid, the physician should allow the blood flow to continue so that it cleans the body. However, al-Rāzī pointed out that it might be red. Sometimes red blood will flow after black bleeding because the vessel opened up after removing the blood clot, which is venous in type.

إذا كان [الدم] أحمر و كان يضعف عليه الجسم  
فهو دم خرج من غير إرادة و لا دفع عن الطبيعة  
فاقطعه مكانك

If the blood is bright red, and its loss is causing weakness in the body, then it is blood which cannot be controlled and does not stop by itself. Therefore, stop the bleeding immediately.[34]

#### Types of Hemorrhoids

Al-Rāzī claims to have seen several different kinds of hemorrhoids. In this he mentioned what would we call today swollen, external hemorrhoids.

رأيت من البواسير ضروباً مختلفة جداً و أعجب ما  
رأيت منها شيئاً يشبه النفخات التي في بطون  
السماك

I have seen extremely varied types of hemorrhoids. The strangest type I have seen was one which resembled the bloated sacs [swim bladder] inside a fish's belly.[34]

Sarābiyūn (2nd half of 9th CE)<sup>8</sup> identified three types of hemorrhoids (Figure 1).

سراييون أنواع البواسير ثلاثة: طوال شبيهة بالفجل التي تسمى الفجلية و منها عراض تشبه حب العنب و منها ما يشبه التوت و شرها النوع الأول و شرها أيضاً ما قرب من الذكر لأنه إذا توجع احتبس البول فأما التي إلى الخلف فهي أقل رداءة و كذلك ما كان خارجاً من الشرج أو قريباً منه فإنه أسهل و الداخلة أشد و منها عمى و هي التي لا يسيل منها شيء فاحتل في فتح هذه فإنها توجع حتى إذا انبعث منها الدم سكن الوجع البتة و فتحها يكوم بأن تَطْلِيهَا بعصارة بخور مريم أو بعصارة البصل الأبيض و نحوهما

Sarābiyūn [said]: Hemorrhoids have three types. [The first is] long, resembling radishes, called “the radish type.” [The second is] wide like grapes. [The third] resembles mulberries. The worst is the first type. [The hemorrhoids] which are anterior and near to the penis are also very bad, since when they become painful, they cause urinary retention. As for the hemorrhoids closer to the anus, they are less harmful. Similarly, those which are external to the anus or close to it are also easier. The internal hemorrhoids are bad. Among these are the “blind hemorrhoids.” These are the ones from which no discharge emerges. Try to lance these, because when blood flows from them, the pain stops immediately. You can open them by swabbing them with a cream extract of cyclamen or cream extract of white onion or something similar.[44-5]

Today we identify the hemorrhoids that are near to the penis as anterior side, and we also recognize them as more serious than the posterior hemorrhoids. The nonbleeding type is blind and painful

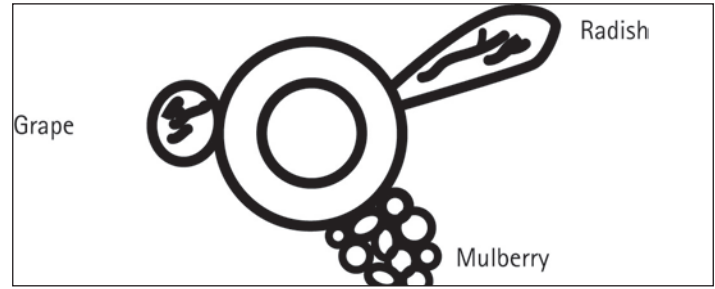


Figure 1. Sarābiyūn's three types of hemorrhoids.

due to thrombosis. Perhaps the modern surgical textbook will classify hemorrhoids into three types: internal, external, and mixed. Each type can be further subdivided into small or large, with or without thrombosis.

Al-Rāzī adds that lancing these “blind hemorrhoids,” which today we identify as thrombotic hemorrhoids, with a sharp instrument is an additional treatment option. He also identified irritation of the urinary bladder due to urinary retention (*waram al-mathāna*) as an additional complication of thrombotic hemorrhoids.[74]

#### Medical Treatment of Hemorrhoids

Scattered throughout this chapter are lists of substances that help alleviate symptoms and heal wounds (Table 1).<sup>9-11</sup>

و مما ينفع أصحاب البواسير الهليلج المرابي الأسود  
المقلو بسمن البقر و ماء الكراث و دهن الجوز  
يكون درهمين و ماء الكراث أوقيتين و حب المقل  
و أطريفل الصغير و المقلباتا دواء جيد إهليلج أسود  
مطجن بسمن البقر و بزر رازيانج بالسوية يدق و  
ينخل و يخلط به مثله من حب الرشاد و يؤخذ  
ملعقة كل يوم مع شراب ممزوج أو يؤخذ خبث  
الحديد منخولاً ثلاثة دراهم حرف أبيض درهمان  
يشرب بأوقية من ماء الكراث مع درهمين من دهن  
الجوز و يضمم الموضع بكراث مسلوقة مطجن  
بسمن البقر و يبخر بأصول الكبر و أصل الحنظل  
و بزر الكراث



Among the medications which benefit those afflicted with hemorrhoids are black jam of Indian and Afghan belleric tree fried with cow fat and leek juice and two dirhams of walnut fat. There should be two Awqiyas of leek juice. Also, there should be seed of balsamadendron africanum, Menyanthes trifoliata Menyanthaceae, and gardencress pepperweed. Another good medicine: [Take] black jam of Indian and Afghan belleric tree baked with cow fat and fennel seed in equal parts. Pound it, then sift it, and then mix it with an equal part of gardencress pepperweed. Mix a spoonful in a drink every day. Or [take] three dirhams of sifted iron rust and two dirhams of white pepperweed and drink them with an awqiya [118 grams] of leek water with two dirhams of walnut oil. Cover the hemorrhoid with boiled leeks baked with cow fat. Smoke the hemorrhoid with caper roots and bitter melon roots and leek seeds.[74]

Al-Rāzī wrote that blind hemorrhoids (thrombotic) are painful and need to be punctured (lanced) open and treated with an ointment of round-leaved cyclamen and belleric tree fried in cow fat, leeks, and walnut oil.[74]

He recommended for painful inflamed swollen hemorrhoids the application of a dressing of mixed leeks, onion, and chamomile or a dressing of king clover, chamomile and linseed[43], hot water[52] to shrink the hemorrhoids and smoking in campiphora africanum to relieve the pain and swelling.[58] He describes cold compresses for swollen hemorrhoids.

Al-Rāzī mentioned the following treatments to ease the pain in the anal area:

1. Enema mixture of cooked king clover with wine until it becomes [ritually] pure and mix with yellow egg, add fenugreek (*Trigonell foenum*), linseed, Faba vulgaris, and Viola odorata and use it as dressing on swollen hemorrhoids.
2. Suppository composed of camel hump fat, leeks, *campiphora africanum* (mukul), sesame oil, and chicken fat. Other types of suppositories include immersing a piece of cotton in honey and spray burned black cumin on it or a suppository of water lily (Nuphar).[43]
3. Enema of yellow egg heated with rose oil. Cook

king clover with grapes and mix with yellow egg, fenugreek, linseed Faba vulgaris, and Viola odorata.[62]

4. Orally take an equal dose of three types of Indian and Afghan belleric tree mixed with apricot oil, honey, and juniper.[63]

If the blood is bright red and is causing weakness and faintness, the physician should stop the bleeding by using alum (*Quercus ilex*) gallnuts paste for three days to dry the hemorrhoid and then apply extract of apricot oil.[33-4,37] This is another example of al-Rāzī's medical treatments.

#### Surgical Treatment of Hemorrhoids

Al-Rāzī had an excellent understanding of the sphincter muscle. which guided his recommendations for surgical treatment.

إن هذه العضلة ليس لها من الذهاب في عرض  
الجسم كثير عمق و لا يكاد يقع عليه باسور إلا  
خارجاً عنها فإذا خزم قطع العضلة في عرض البدن  
فقول [جالينوس] اسرف في قطع العضلة إنما هو  
في طول الجسم لا في عرضه و يستدل على ذلك  
من أن الإنسان إذا شد هذه العضلة رآها تجذب  
المقعدة إلى فوق جذباً شديداً و هذا فعلها لأن هذه  
العضلة خلقت هاهنا لمنفعة أن تغلق الدبر و أن  
تشيل المقعدة إذا خرجت فيدل ذلك على أن جل  
فعلها للبواسير يضمها حتى يكون كالصحيح

This [sphincter] muscle does not have much depth in a longitudinal plane. A hemorrhoid rarely rests upon it, with the exception of external hemorrhoids. If the hemorrhoid is ligated, the muscle is cut longitudinally across the body. So Galen's saying "cut deeply" is restricted to the longitudinal axis of the body, not transversely. Additional evidence for this is that a human who contracts this muscle will see it pull strongly the anus upwards. This is its appropriate action because

**Table 1. Partial list of substances mentioned by al-Rāzī for the treatment of anorectal disease and their equivalent English names.<sup>9-11</sup>**

Aloe Vera (Cactus)	صَبْر	Alum (Quercus ilex)	شَبَّ	Black Cumin	شُوَيْر الحبة السوداء
Black Myrobalan (belleric)	ابليلج املج	Black Night Shad	عَنْب الثَّعْلَب	Burned Paper	قُرطاس مَحْرُوق
Commiphora Africanum (Mukul)	مُقَل	Caper ( <i>Capparis spinosa</i> L.)	الكَبَر	Carob Tree	خَرْثُوب
Cashew Nuts	البلاذر	Chamomilla	بَابُوج	Chicken Fat	دِهْن الدَجَاج
Colocynth, bitter melon ( <i>Citrakus Colocynthis</i> )	الحَنْظَل	Coral	بَسَد	Curcuma Longa	كُرْكُم
Deer horn	قَرْن الأَئِيل	Dragon gum tree ( <i>Pterocarpus draco</i> L.)	أُخْوِينْدِم	Extract of Apricot Oil	دِهْن المِشْمِش
Eye Salves	شِيَاْف	<i>Fava vulgaris</i>	بَاقِلِي	Fennel ( <i>Foeniculum vulgare</i> )	رَازِيَانَج
Fenugreek ( <i>Trigonella foenum-graecum</i> )	الحَلْبَة	Frankin (Excudation)	كَنْدِرا	Gallnuts	عَفْص
Gardencreep pepperweed ( <i>Lepidium sativum</i> )	مَقْلِيَاثَا	Gum of the red juniper, sandaracha	سَنْدَرُوس	Horned poppy ( <i>Glaucium corniculatum (flavium)</i> )	مَامِيْثَا
Indian and Afghan belleric tree	إِهْلِيلِج	Iron Rust	خَبْث الحَدِيد	King Clover	إِكْلِيل المَلِك
Leeks	كِرَاث	Lentil	عَدَس	Linseed	كَيْتَان
Lyceumafrum	حَضَض	Malabar Cinnamon ( <i>Cinnamomum citriodorum</i> )	المَرخ	<i>Menyanthes trifoliata</i> Menyanthaceae (active ingredient saponin)	أَطْرِيفَل
Myrtle ( <i>Myrtus communis</i> )	آس رِيحَان	Opium	أَفْيُون	Papyrus	بَرْدِي
Peach Oil	دِهْن الخَوْخ	Persian Giant Fennel ( <i>Ferula asafoetida</i> )	يَحْسَكِب	Pomegranate	رُْمَان
Poppy seeds	الخِشْخَاش	Rose Oil	دِهْن الوَرْد	Round cardomon ( <i>Amomum cardamon</i> L.)	قَاقِلِي
Round-Leaved Cyclamen ( <i>Cyclamen coum</i> )	بُخُور مَرِيْم	Saffron	زَعْفَرَان	Seashells (Conch)	وَدَع
Sesame Oil	سِمْسِم	Sumac	سُمَاق	True Senna ( <i>Senna alexandrina</i> Mill.)	سَنَامِكِي
Verdigris	زَنْجَار	<i>Viola odorata</i>	بَانْفِسِج	Vitriols Oil	زَاج قَلْقَطَار
Water Lily	تَيْلُوفَر	White Lead (Ceruse)	إِسْفِيدَاچ	Yellow Amber	عَمِر كَهْرَب
Zinc	تُوتِيَاء				

the muscle was created for the benefit of closing the anal passage and lifting the anus [pelvic floor] when it protrudes. This is evidenced by the fact that most of the anal muscle's impact on hemorrhoids is to shrink them.[53-4]

In this passage, al-Rāzī describes the functions of the inner circular sphincter muscle and the outer external sphincter muscle of the anus, as well as the puborectalis, which sits upon them both. Al-Rāzī correctly identified the puborectalis muscle as the muscle that controls the functions of continence in the anal area. If surgery was required, his surgical technique avoided cutting of the puborectalis muscle.

#### External Hemorrhoids

Al-Rāzī discussed three types of surgical treatment for hemorrhoids: ligation, ligation with tightening, and excision. These differ from the current standards of surgical treatment of hemorrhoids.

إذا أردت خزم البواسير فانظر فما كان منها لا  
ينفذ الميل فيه و لا يصل إلى الأصبع الأفوق كثيراً  
فتوقه فإنك إن خزمته استرخت المقعدة لأن في  
ذلك قطع العضلة كلها و ما كان يصل إليه  
أصبعك أسفل فلا تقبه فإنه لا ينقطع من العضلة إلا  
قليلاً. و قد تخزم البواسير إذا أردت ذلك فليكن  
خزمك بها بشعر مفتول على مثل ما يعمل  
الصيداؤون بالجعر فإنه أبلغ و أسرع فإن لم يتهياً  
فبالزبر فإنه جيد بالغ و توق كل ما كان بعيداً  
يحتاج أن يدخل في وسط لحم كثيراً فإذا خزمت  
فلا تشد أول يوم و استعمل جلوس المريض في الماء  
الحار و المرخ بالدهن و الضماد المرخي و الدهن  
الكثير و تواتر ذلك و ضمده قبل ذلك لئلا يحدث  
على العليل التشنج فإذا رأيت أنه يريد أن تحدث

أعراض ردية فحل الخزم و متى لم يعرض عارض  
ردي فشد كل يوم إلى أن يفرغ

If you want to ligate hemorrhoids, first check if the probe cannot pass through it and your middle finger cannot easily reach it. If these are the case, then be careful. If you ligate, the rectum will become loose [and incontinent] because the entire muscle will be cut. As for those hemorrhoids which your finger can reach, don't be scared to proceed with ligation as it will only cut a small portion of the muscle. You may ligate hemorrhoids if you want. Use twisted hair like hunters do with hyenas [?] because that reaches farther and faster. If this is not available, then use a leather strap [?], as that is also good and reaches far. Be cautious as you reach farther and deeper into thick flesh. When you ligate, don't tighten the first day. Ask the patient to sit in hot water and fatty stew and Malabar cinnamon dressings and lots of fat. Repeat this several times. Apply dressings before this so that the patient does not experience spasms. If you see that side-effects seem ready to occur, then untie the ligature. If no side-effects appear, then tighten the ligature each day until the process is complete.[52-3]

الخزم إن كان صغيراً فاخزم حوله و إن كان كبيراً  
فأدخل ابرة في وسطه و اخزمه بنصفين أو على  
قدر ما ترى فإذا خزمت فضع عليه كراتاً أو بصلاً  
مسلوقاً قد خبص بسمن لئلا يرم و يوجع وجعاً  
شديداً و دخنه بسنام الجمل و المقل

If the hemorrhoid is small, ligate around it. If it is big, insert a needle into its center and ligate it in two halves, or as you see fit. When you complete the ligation, apply boiled leeks or onions mixed with animal fat so that it will not swell and become extremely painful. Steam it with with camel fat and *camiphora africanum*.

Al-Rāzī recommended ligation of hemorrhoids

by pulling the buttocks apart to see them clearly and inserting a finger in the rectum. If it can reach the lower sphincter, the physician can ligate the hemorrhoid, and it will not affect the sphincter muscle. The hemorrhoid can be simple and small. This can be treated with silk tie around the base. Large hemorrhoids can be suture ligated by using twisted hair, silk, or cotton on a needle. The physician should insert the needle at the middle base of the hemorrhoid and tie it in two halves (Figure 2).[53,80] If the hemorrhoids are multiple, al-Rāzī recommended not to ligate all of them at the same time.[82]

Rubber band ligation is used today. A surgeon uses a banding instrument to slip the rubber band over the base of the internal hemorrhoid. The rubber band will cut off the blood supply of the hemorrhoid, and the hemorrhoid will slough off.

Ibn al-Quff al-Karakī (d. 685 AH/1286 CE) described another ligation technique:

و أما الشد فهو أن تشد الباسورة عند أصلها شداً معتدلاً ثم يربط الخيط بنا شوطة و يترك يوماً و ليلة ثم يحل الشد و يربط أقوى من ذلك و يترك يوماً و ليلة ثم كذلك في اليوم الآخر إلى حين تسقط الباسورة

Regarding [the technique of] tightening [the hemorrhoid], it begins by tightening with medium force the hemorrhoid at its base with string attached to a piece of wood and leaving it for a 24-hour period. Then release the pull and then tie it more tightly than before and then leave it for a 24-hour period. Do this each day until the hemorrhoid falls off.[219 in *al-Umda*]<sup>3</sup>

The final technique is simple excision.

و قطعها [أي الباسورة] أن تأخذها بالقلب و اقطعها من أصلها بعد شدتها إليك نعماً و تجعل على الموضع بعد أن تدع الموضع يسيل منه الدم حتى يضعف و يحتبس الصبر و الكندر مسوحوقين و دم الأخوين و شياف ماميثا و قاقيا و نحو ذلك

Excision [of the hemorrhoid] is done by grasping it with a hook and cutting it from its base after pulling it towards you gently. After letting the location of the excision bleed until the flow slows and stops, place on it ground aloe vera and frankin and extract of dragon gum tree and eye salves of horned poppy and round cardomom.[80]

Al-Rāzī recommended applying an astringent powder (Kal Katar) vitriol oil, leeks, cooked onions, camel hump fat on the site of surgery with dressing or use a mixture of clay, yellow amber, coral, deer horn, paper and papyrus.[80]

He also used mixtures of cumin, apricot oil, peach, and camel hump fat to ease anal pain. He advised using sitz baths by soaking the anal area with solution using skin of pomegranate, which acts as a constricting agent and prevents pain from the edema of the ligation.[81]

In today's surgical practice, we do excision for the external hemorrhoids and rubber band ligation for the internal hemorrhoids.

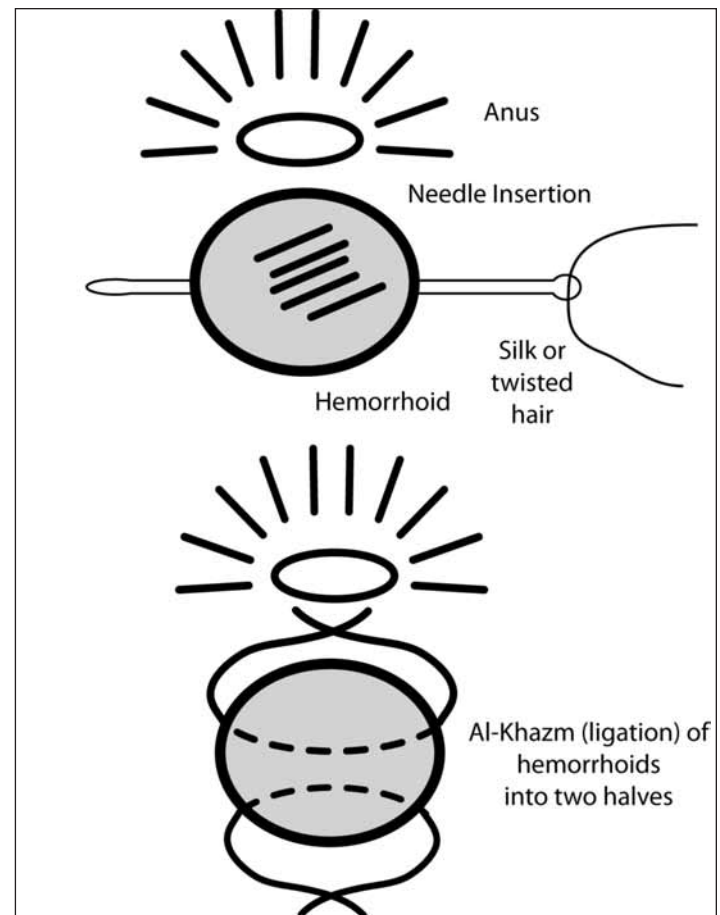


Figure 2. Ligation treatment for hemorrhoids.



### Complications

Al-Rāzī recommended using a powdered mixture of dragon gum tree, leeks, and gallnuts crushed together and then applied topically with a dressing. Another recommended mixture consisted of deer horn, seashells (conch), burned paper, papyrus, coral, and myrtle. Another mixture mentioned in the text is yellow amber, rosebud, lyceumafrum, and pomegranate peels. If the patient bleeds and becomes weak and the heart palpitates, the physician should try to keep the patient warm, feed him red meat and use musk or *curcuma longa*. If there is large swelling, apply a dressing and administer a laxative.[51,81]

If the patient develops fecal incontinence caused by cutting the sphincter partially or fully and cannot contract and close the anal orifice, the sphincter should be repaired by surturing if possible.[49,53] It is useful to sit in a constricting agent like curcuma water.

### Internal Hemorrhoids

Al-Rāzī recommended treating internal hemorrhoids with chemical cautery, suppository and a caustic substance. The head of the internal hemorrhoid should be pulled out by suction cup and then excised to prevent it from receding, and it should be tied with twisted hair. A mixture of paste composed of black myrobalan (belleric), iron rust mixed with honey, and animal fat relieves the pain and discomfort. Vitriol powder can be used with tight dressing. Bowel movements should be discouraged for 24-hours to prevent bleeding. Afterwards, a laxative should be used in moderation.[61-2]

### Fistula in Ano

If the patient complains of drainage from a fistula, al-Rāzī recommended that the physician examine him and see if it is in one place.

أدخل الميل في الناصور و أدخل السبابة من اليد اليسرى في الحلقة حتى تلمس رأس المجس ثم أمر العليل أن يضم مقعدته بقوة و تفقد كيف قوة الضم فوق أصبعك و ادفعها إلى فوق فإن رأيت أن فوق موضع أقصى الناصور موضع كبير من العضلة القابضة فإنه مما يجوز أن يخزم و بالضد

Insert the probe into the fistula. Insert the index finger of your left hand in the anus until you touch the tip of the probe. Ask the patient to close his anal sphincter strongly and check the strength of the contraction against your finger. Push the muscle upwards, and, if you see that that a large area of the muscle is above the tip of the fistula, then ligation is possible and vice versa.[59]

أيضاً للناصور في المقعدة أدخل فيه المجس و حكه و يكون المجس خشناً كالمبرد فتدخله و تحكه ثم أدخل فيه فتيلة بمرهم زنجار حاد مرات و تحكه كل مرة فإذا نقصت العلاج فأدخل فيه صبراً و كندراً فإنه يلزمه و يلحمه

Introduce the file instrument into [the fistula tract] and scrape it. The file instrument should be rough, like sandpaper. Introduce it and scrape. Then introduce into it a wick soaked with caustic verdigras ointment. If the fistula tract shrinks, then the treatment is to introduce into it aloe vera and frankin. This will stick to it, and it will heal.[77]

النواصير العارضة في المقعدة ما كان منها قريباً من تجويف المقعدة فالخطر فيه أقل لأنه لا يذهب معه كل العضلة بل قطعة منها فلا يذهب فعل هذا العضل ألبتة و أما ما كان بعيداً من تجويف المقعدة فالخطر فيه عظيم لأنه ينقطع العضلة كلها عند الخزم فلا يمكن صاحبه إمساك الغائط

Regarding transverse fistula in the anus, if they are close to the anal opening, the danger is less. That is because the entire muscle will not go with it, only a piece, and thus its function will not disappear entirely. If they are far away from the anal opening, the danger is great because the entire muscle is cut during ligation and bowel incontinence results (Figure 3).[32]

نواصير المقعدة متى لم تكن نافذة جعل فيها دواء  
 حاد ثم سمن ثم مرهم أسود حتى يبرأ و النافذة  
 يخرج منها الزبل و الريح تحتاج أن تخزم فإن كانت  
 له أفواه عدة فاختزم بعضها إلى بعض

If the sinus is blind (the fistula is closed), apply a caustic agent, use animal fat and black ointment until it heals. If it is open and stool and gas pass through it, incision is needed. If it has many openings, connect each of them to the others.[55]

If the main fistula has many orifices, al-Rāzī recommended that all of them should be cut open except the deepest fistula closest to the anal sphincter.[10,55] When the discharge of some of the sinuses stops, it will close spontaneously.[59]

As stated, introduce the rough probe into the sinus and insert the index finger in the anal canal to reach the end of the probe. If you see it takes a large part of the muscle, do not cut the sphincter muscle and guide the rough probe through the fistula tract and scrape it several times until it bleeds and pack the fistula tract with a wick immersed in verdigris. Repeat scraping it until the fistula tract shrinks in size. Then, fill it with extract of frankin (excudation) and aloe vera (cactus).[77] The most chronic sinus is difficult to treat and will take a long time to heal.

This will act as a plug and heal with granulation tissue, as is mentioned in the literature today. The anal fistula plug described by Champagne et al used today is a bioabsorbable xenograft made of lyophilized porcine intestinal submucosa used to treat deep transphincteric fistula in ano (Figure 4).<sup>12</sup>

### Rectal Abscess and Swelling

Al-Rāzī stated that a rectal abscess usually occurs after surgical excision of hemorrhoids, fissure, or fistula. He recommended the use a mixture composed of white eggs with crushed rose oil, opiate, and white lead (asphedag) to relieve the pain and discomfort and apply heating pad until it drains. For hot or warm anal swelling, he suggested a mixture of saffron, opium and yellow egg, Black Night Shade, and rose oil.[40]

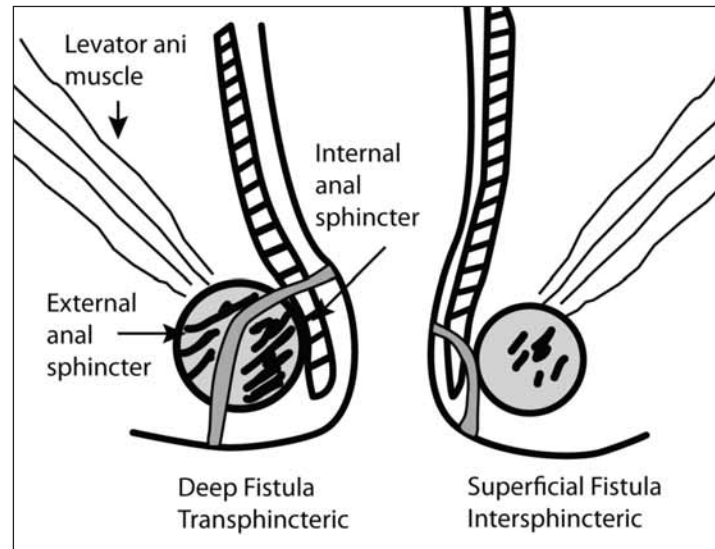


Figure 3. Types of fistula in ano.

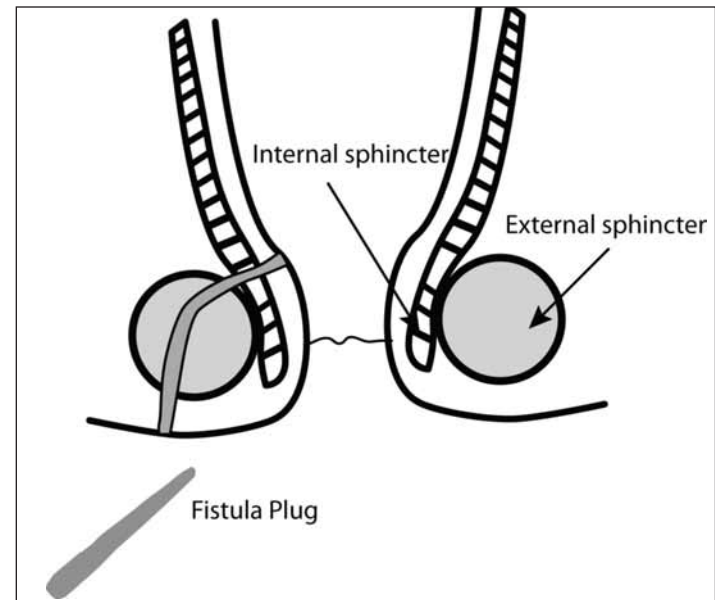


Figure 4. Anal fistula plug for transphincteric fistula.

### Fissure in Ano

Al-Rāzī believed that fissure is caused by constipation due to severe dryness of the stool, which causes severe pain and itching. The treatment is to use laxatives and topical ointment mixtures to relieve the pain. One mixture is duck fat, white lead, alum, saffron, and rose water. [29,83] A second mixture is king clover, poppy seeds, opium, egg yolk, and zinc. A third mixture is alum, mukul, and juniper.[30] Another mixture is frankin, camel hump fat, and Persian giant fennel.

### Rectal Prolapse

Al-Rāzī believed that rectal prolapse is caused by a loose anal sphincter caused by tumor or weakness

in the anal sphincter.[53] He suggested it be treated with an astringent suppository. According to al-Rāzī, a simple case can be reduced by strapping the buttocks and letting the patient sit in a bath of astringent agent composed of rose oil, lent, and sumac. The strapping white bandage should be used for one hour and released and repeated again until the rectum does not protrude.

Today physicians will use wide tape strapping of the buttocks for 24 hours and released and repeated again until the rectum does not protrude.

### Pruritis Ani

Al-Rāzī mentioned that anal itching may be caused by pinworms or an ulcer, each of which should be treated accordingly. The treatment for

idiopathic anal itching is to wipe the anal area with eye salves (sheaf) or vinegar with rose oil or use verdigris solution.[54]

### Surgical Instruments

Finally, we add that some ancient anorectal surgical instruments are similar to instruments used today (Figure 5).

### Conclusion

The surgical treatments al-Rāzī recommended for anorectal disease share surprising similarities to the colorectal surgical practices of today, especially the emphasis on avoiding cutting the anal sphincter for surgery on hemorrhoids and fistulas to avoid incontinence. His description of the treatment of

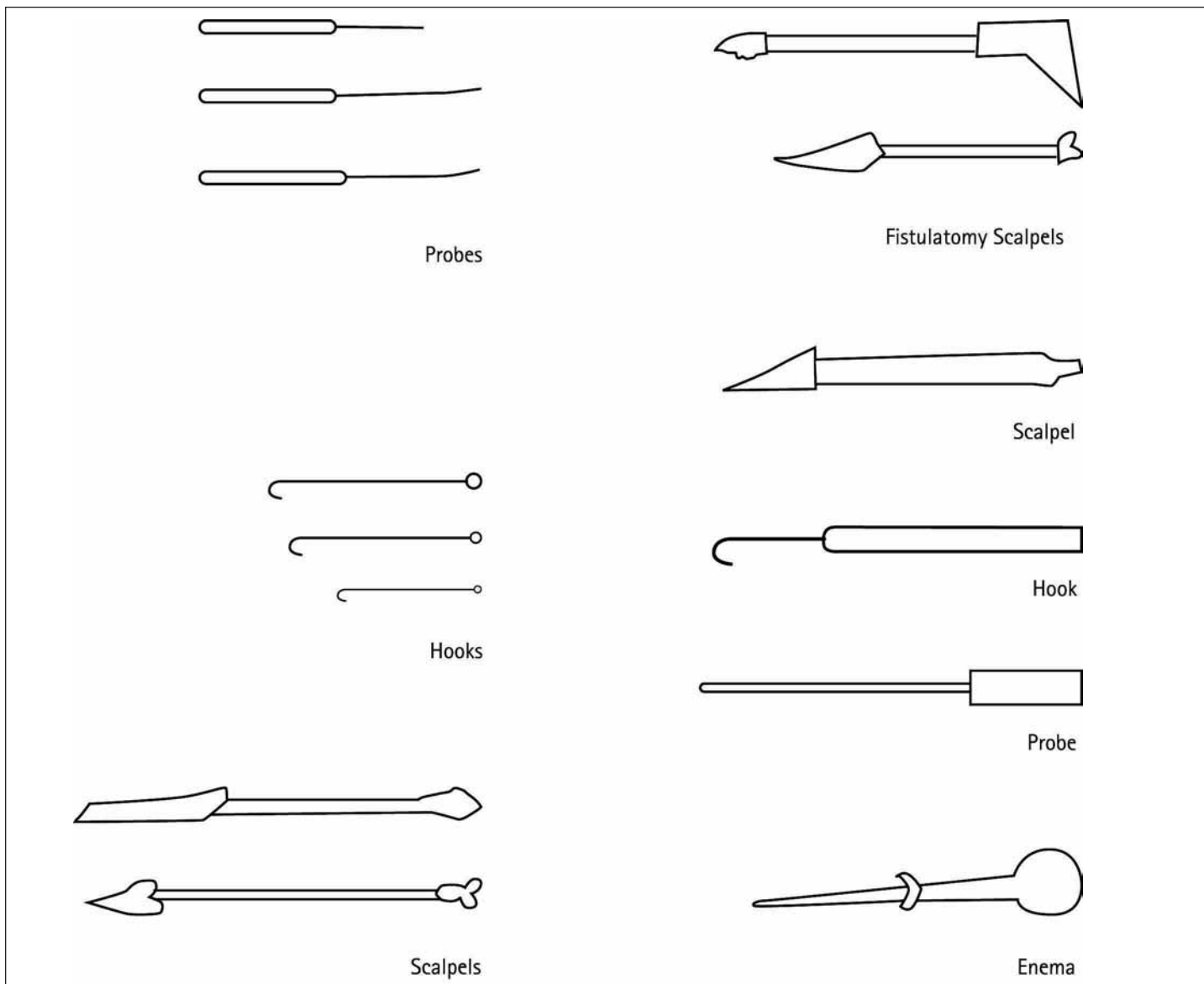


Figure 5. Al-Zahrāwī (Albucasis) anorectal surgical instruments.<sup>13</sup>

hemorrhoids would sound familiar to the modern physician.

His treatment for fistula in ano was amazingly similar to our approach, especially when he describes curetting the fistula tract and filling it with agents that have similar characteristics to the anal plug that is used today to cure these difficult fistulas.

Al-Rāzī's extensive experience and accurate clinical observation allowed him to manage anorectal disease well. The details of the symptoms and treatment described in the manuscript prove that the diagnosis and management of anal rectal disease were carried out with the utmost care and diligence."

### Acknowledgements

We would like to thank Mr. Ayman Fadel, the Assistant Editor of JIMA, for his active and persistent participation in editing and translating the text and obtaining the reference sources. His efforts are greatly appreciated. Also, we would like to thank Ms. Teresa Shields, Dr. al-Humadi's nurse, for her efforts in typing and preparing the manuscript for submission.

### References

1. Abū Bakr Muḥammad ibn Zakariyyā al-Rāzī. Kitāb al-ḥawī fī al-ṭibb. Hyderabad: Osmania University; 1962.
2. Abū 'Alī al-Ḥusayn ibn Sīnā. al-Qānūn fī āṭ-ṭibb. Ṭab'a ḡadīda bi-āl-offset 'an ṭab'at Būlāq. Bayrūt: Dār Sādir, [ca. 1970].
3. Abū al-Faraj ibn Ya`qūb ibn Ishāq ibn al-Quff al-Karakī. Kitāb al-'umda fī al-jirāḥa. Hyderabad: Dā'ira al-ma`ārif al-'uthmāniyya; 1937.
4. National Library of Medicine. U.S. National Institutes of Health. Islamic medical manuscripts at the National Library of Medicine: authors, translators and commentators of treatises. [Web page on internet]. Available from <http://www.nlm.nih.gov/hmd/arabic/authors.html> [Updated 2009 Jan 8; accessed 2009 Nov 23].
5. Savage-Smith E. Medicine. In: Rashed R, Morelon R (editors). Encyclopedia of the history of Arabic science. Volume 3: Technology, alchemy and life sciences. London: Routledge; 1996:904-62.
6. Pormann PE. The Oriental tradition of Paul of Aegina's Pragmateia. Brill: Leiden; 2004.
7. Abū Bakr Muḥammad ibn Zakariyyā al-Rāzī. Al-Manṣūrī fī al-ṭibb. Al-Kuwait: Manshurāt ma`had al-makhtūṭāt; 1987.
8. Pormann PE. Yūḥannā ibn Sarābiyūn: further studies into the transmission of his works. Arabic Sciences and Philosophy. 2004;14:233-62.
9. Abū al-Faraj ibn Ya`qūb ibn Ishāq ibn al-Quff al-Karakī. Jāmi` al-gharaḍ fī ḥifẓ al-ṣiḥḥa wa daf` al-maraḍ. Hamarneh SK (editor). Amman, Jordan: al-Jāmi`a al-urduniyya; 1989.
10. Al-Shahāwī MM. Sharḥ ba`ḍ mufradāt al-a`shāb min kitāb al-dā' wa al-dawā' fī al-tibb al-qadīm bi taṣarruf. khayma.com/hawaj [web site on Internet]. Available from <http://www.khayma.com/hawaj/herblist.htm>. [Accessed 2009 Nov 9].
11. Global Biodiversity Information Facility. GBIF data portal. Copenhagen, Denmark. Available at <http://data.gbif.org>. Accessed 2008 Sep 7.
12. Champagne BJ, O'Connor LM, Ferguson M, et al. Efficacy of anal fistula plug in closure of Cryptoglandular fistulas: Long-term follow-up. Dis Colon Rectum 2006;3:1817-1821.
13. Al-Ghazal SK. Al-Zahrawi (Albucasis) - a light in the dark middle ages in Europe. J Inter Soc History Islam Med. 2003;1:37-8. Available at: <http://www.ishim.net/ishimj/3/08.pdf>.