

RIGHT MIDDLE LOBE SYNDROME?

Anwer Rasheed, M.D.* , Bashir A. Chaudhary, M.D.** ,
William A. Speir, Jr., M.D.***

Section of Pulmonary Diseases - Department of Medicine
Medical College of Georgia, Augusta, Georgia

Case History

An 83 year old black female was referred to the Medical College of Georgia, Eugene Talmadge Memorial Hospital for bronchoscopy to evaluate her "right middle lobe syndrome". She had presented to her local physician because of progressive weakness and anorexia.

Physical examination revealed slight dullness on

*Research Assistant

**Associate Professor of Medicine

***Professor of Medicine

Chief, Section of Pulmonary Diseases

percussion and reduced condition of breath sounds in the right middle and lower lobe areas. Remainder of the physical examination was normal. The chest roentgenogram showed a large radiodensity obscuring the right heart border (Fig. 1A, B). Routine laboratory investigations were negative except for anaemia of chronic disease. Sputum examination for acid fast bacilli and a PPD skin test were negative. After reviewing the clinical information and the chest roentgenogram a procedure was recommended.

Achalasia of Esophagus

The lateral chest roentgenogram shows a large radiodensity in the lower lobe area, anterior

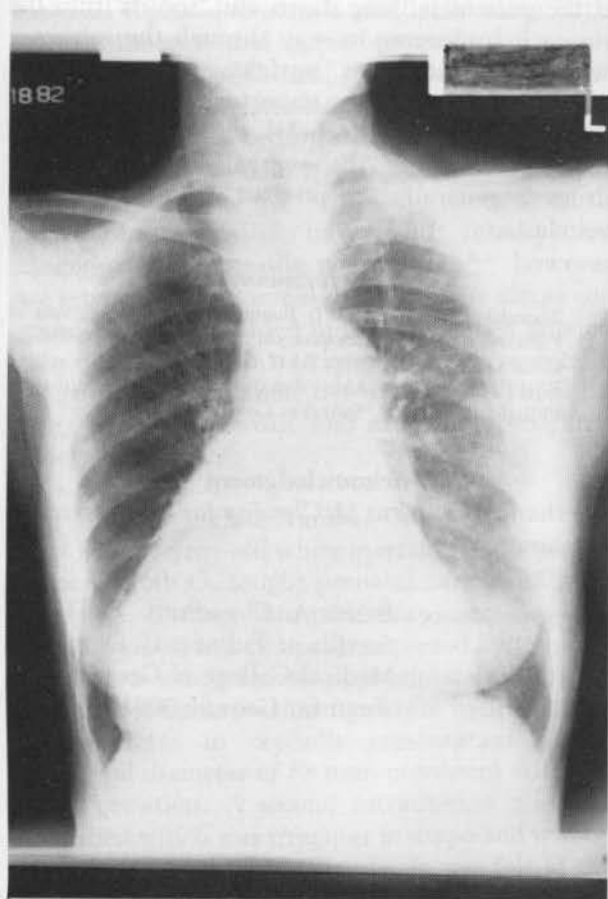


Fig. 1-A PA Chest roentgenogram

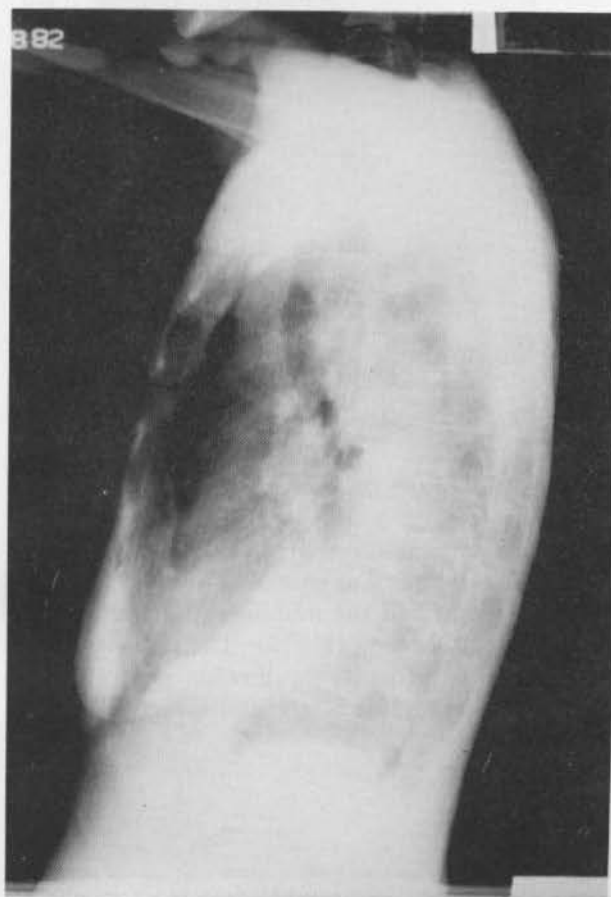


Fig. 1-B Lateral Chest roentgenogram

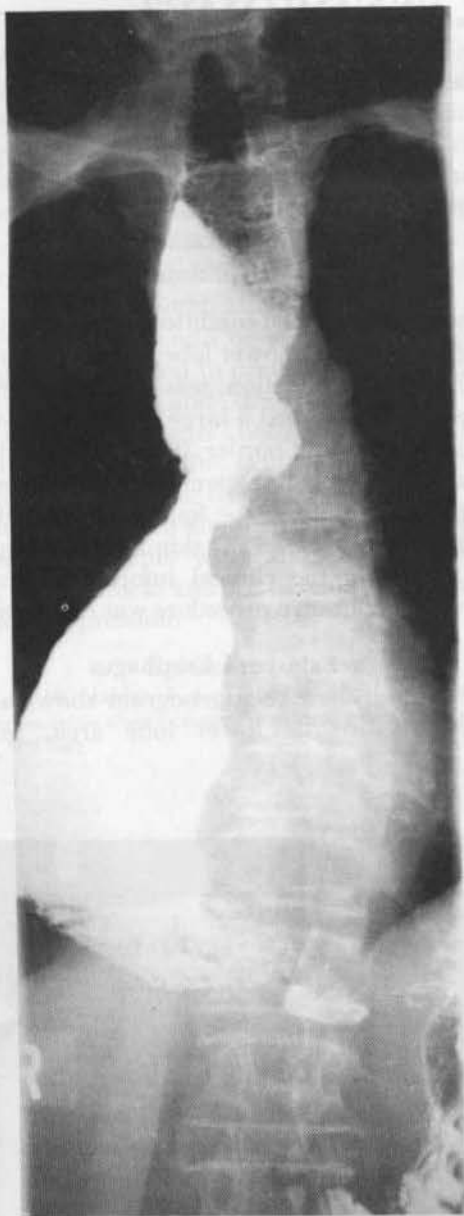

Fig. 2 Barium swallow showing dilated esophagus

displacement of the trachea and an air-fluid level in the upper esophagus (Fig. 1-B). A barium swallow showed no peristaltic activity below the thoracic inlet. The esophagus was markedly dilated and was right of mid-line in the middle and lower portion with distal narrowing (Fig. 2). The patient admitted to having difficulty swallowing solid food for many years. Esophagoscopy and CT scan showed

dilation of esophagus. No other intrinsic or extrinsic esophageal abnormality was found.

In the early stages of achalasia of esophagus, a plain chest roentgenogram may be normal. With progressive dilation of the esophagus, there may be widening of right mediastinum, at times with a 'double contour' of the heart shadow. If the right heart border remains visible, the diagnosis of a structure posterior to heart may be suggested. However, with extreme dilation of esophagus, the right heart border may be obscured. There may be evidence of pneumonitis or atelectasis resulting from aspiration of esophageal contents. An air-fluid level in the region of aortic arch or above is often present and may be the first indication of the disorder. A lateral film often shows anterior deviation of trachea with a mottled opacity behind it. The mottling results from food residue in the esophagus. Barium swallow shows the dilation, absent peristaltic activity and persistent failure of the lower esophageal sphincter to relax.

The dilated esophagus may have a smooth narrowing in the distal 2-4 cm. giving a 'rat-tail' appearance. In the later stages, it may be so dilated and tortuous that it is called a 'sigmoid esophagus'. Barium stays above the closed esophageal sphincter if the patient is lying down and 'squirts' into the stomach by forcing its way through the sphincter when the patient is upright. Endoscopy and manometric studies are important components of a work-up, and a "Mecholyl test" demonstrating hypersensitivity of the esophagus to cholinergic drugs is generally accepted as diagnostic of true achalasia.

References

1. Zboralske FF, Dodds WJ: Roentgenographic diagnosis of Primary disorder of esophageal motility. *The Radiologic Clinics of North America* 7:147, 1969.
2. Ellis FH, Olsen AM: *Achalasia of the Esophagus*. Philadelphia, W. B. Saunders Co. 1969.

Acknowledgment

We thank Mrs. Nora McClendon for her secretarial assistance.

Correspondence: Bashir A. Chaudhary, M.D.
Section of Pulmonary Diseases
Medical College of Georgia
Augusta, Georgia 30912