

Case Report

Hydatid Disease of the Breast: A Case Report

Mir Mohsin, MS;^{1,2} Iqbal S. Mir, MS;² Naveed N. Shah, MD;³

Saifuddin B. Fakir, MS;¹ Abdul Quadir, MS¹

¹Department of Surgery, JN Medical College Hospital, AMU, Aligarh

²Department of Surgery, Government Gousia Hospital, Srinagar, Kashmir, India

³Department of Chest Medicine, JN Medical College Hospital, AMU, Aligarh

Abstract:

Hydatid disease of the breast is rare and may be confused with other cystic lesions. Radiological findings of hydatid disease of the breast are nonspecific. We report a case of a 30-year-old female with a palpable lump in her left breast. An ultrasound examination of the breast revealed a cystic lesion. Excisional biopsy was done, and histopathology confirmed it to be a hydatid cyst.

Key words: Hydatid disease, breast, treatment.

Introduction

Hydatid disease is caused by the larval form of *Echinococcus granulosus*. Although most prevalent in sheep-raising countries, hydatid disease has a worldwide distribution. Humans are accidental intermediate hosts of this organism.¹⁻³ The liver is the first filter that stops about 75% of the embryos, and the lungs filter another 10%, leaving only 15% to develop into cysts in other organs of the body.² Although more frequent reports have appeared in recent years, hydatid disease of the breast still remains rare and accounts for only 0.2% of all occurrences.^{3,4} We are reporting a case of hydatid disease of a breast in a patient that had been previously operated on for pulmonary hydatidosis.

Case Report

A 30-year-old female presented in the surgical

outpatient department with a history of a slow-growing, painless lump of 8 months duration in her left breast. There was no history of discharge from the nipple. She had no risk factors for breast cancer. The patient had had an operation 5 years earlier for bilateral pulmonary hydatid cysts and had taken albendazole for 2 months postoperatively. Physical examination revealed a circumscribed, freely mobile 4- by 3.5-cm firm mass in the central portion of the breast. There was no cervical or axillary lymphadenopathy. The remainder of the physical examination was unremarkable.

A chest roentgenogram and ultrasonography of abdomen at the time of presentation were normal. A mammogram revealed a well-circumscribed dense lesion without calcification (Figure 1). Ultrasonography of the breast showed a rounded lesion with internal septations and heterogeneous echogenicity in the central portion of the breast (Figure 2). Serum antiechinococcus antibody titre was 1:1200. A titre greater than 1:100 is considered a positive result. Fine needle aspiration (FNA) was performed, and the fluid was subjected to cytological examination, which revealed an abundance of free hooklets. Following FNA, the size of the lump remained unchanged, and an excisional biopsy was

Correspondence should be directed to

Mir Mohsin, MS

House No. 150

Nursingarh, Srinagar, Kashmir, J&K, India.

telephone: 009906488886/ 001942477202

email: m_mohsin@rediffmail.com

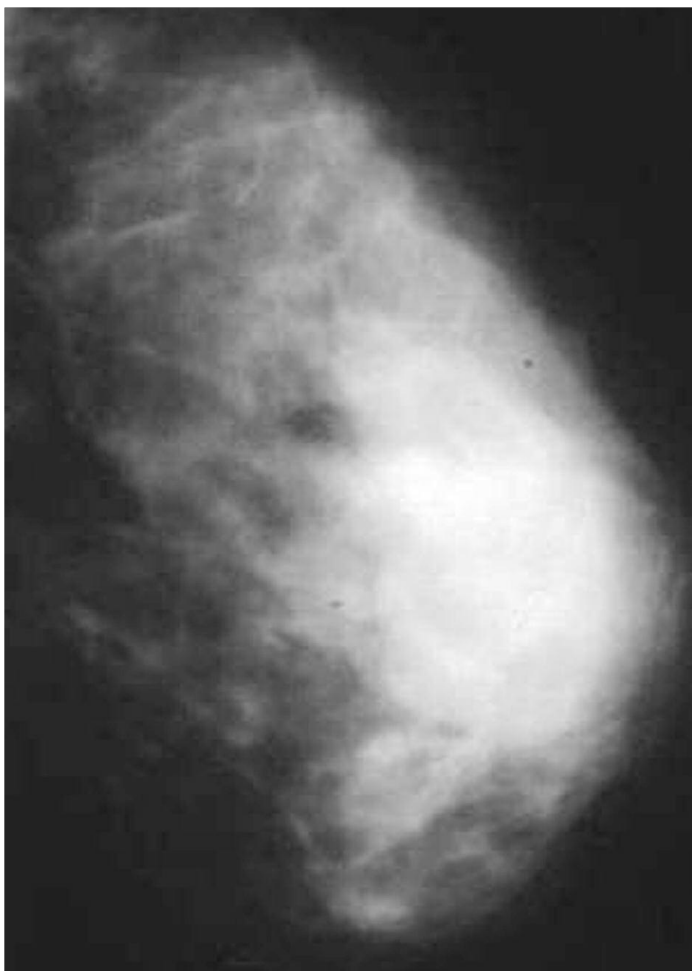


Figure 1. Mammogram of left breast showing a well-circumscribed dense lesion without calcification.

done. The specimen (Figures 3 and 4) was sent for histopathology, which confirmed the diagnosis of hydatid disease.

The patient was put on albendazole 10 mg/kg a day postoperatively for 6 months. She remained free of recurrence 2 years after surgery.

Discussion

Hydatid disease of the breast is rare, accounting for 0.2% of all cases. It can be the only primary site or part of disseminated hydatidosis.^{3,4} It is an important differential diagnosis of breast lumps in endemic areas. It usually presents as a painless slow-growing mass without regional lymphadenopathy. It generally affects women 30-50 years of age, although a range of 26-74 years has been reported.⁵

Screening modalities for diagnosis of breast hydatid disease are ultrasound, mammography, and magnetic resonance imaging (MRI).³ Ultrasonographic appearance of hydatid disease of the breast is variable, ranging from unilocular to mul-

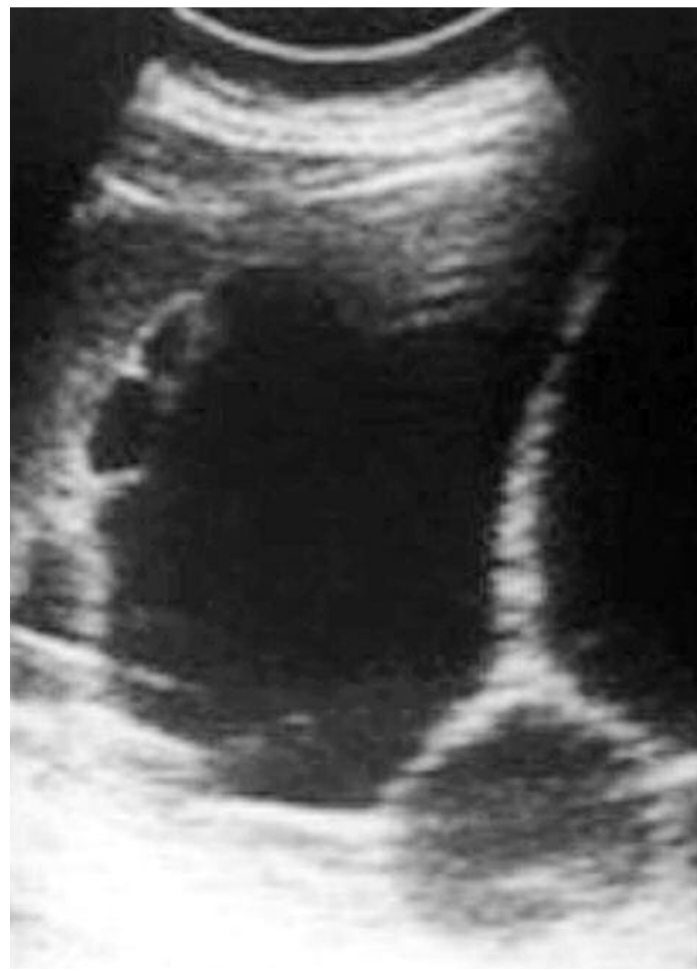

Figure 2. Ultrasonogram of the breast revealing a rounded lesion with internal septations and heterogeneous echogenicity.

tilocular cysts. It may have an appearance indistinguishable from a benign cyst; however, the presence of a thicker wall and a thin layer of calcification within the lesion may suggest a hydatid cyst.⁶

Mammography shows a homogeneous, smooth, circumscribed lesion. The characteristic ring-shaped structures inside the mass can be seen in overpenetrated views. If these structures are not seen, then the differential diagnosis includes cyst, fibroadenoma, phylloides tumor, and, rarely, circumscribed carcinoma.³

Cytological diagnosis of hydatid disease is established by the identification of scoleces, hooklets, or fragments of laminated membrane.⁷ Serological tests—such as enzyme linked immunosorbent assay (ELISA), indirect hemagglutination, and immunoblot techniques—confirm the hydatid origin of a cyst, which imaging techniques diagnose.⁴

Surgery is still the most effective therapy for hydatid disease, which exists in any location,^{1,4} with

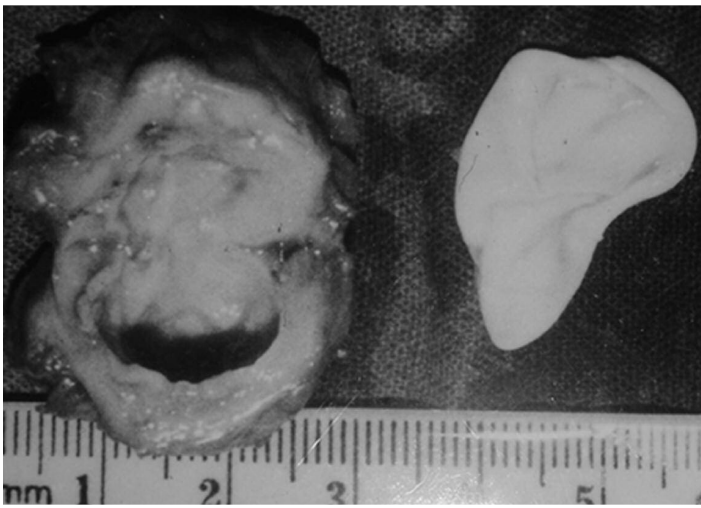


Figure 3. The excised mass specimen after fine needle aspiration.

the principal objectives being total removal of all parasitic elements, avoidance of spillage of contents of the cyst, and removal of the cyst with maximum conservation of the stricken organ. In hydatid disease of the breast, total cyst excision is the treatment of choice.^{3,4,8}

Recurrent disease has been reported in 10% of patients undergoing hydatid cyst surgery.¹ Perioperative chemotherapy using albendazole has been shown to decrease the incidence of recurrent disease.⁹ However, albendazole may not prevent disease recurrence in a distant site,⁴ as in our case.

Follow-up studies should be complemented with serological tests. Blood titers may decrease slowly over months to years after complete removal of disease.¹⁰ Hence, a positive serological test during follow up is not necessarily diagnostic of recurrence, but a rising titre is. The preferred method of identifying recurrent disease, in addition to clinical and serological evaluation, is ultrasonography and computed tomography (CT) scans.¹⁰ In conclusion, hydatid disease of the breast is rare but should be considered in the differential diagnosis of breast lumps. The ideal treatment is complete excision of the cyst without spillage.

Acknowledgement

We acknowledge the help Mir Muneeb provided in drafting this manuscript.

References

1. Dziri C. Hydatid disease—continuing serious public

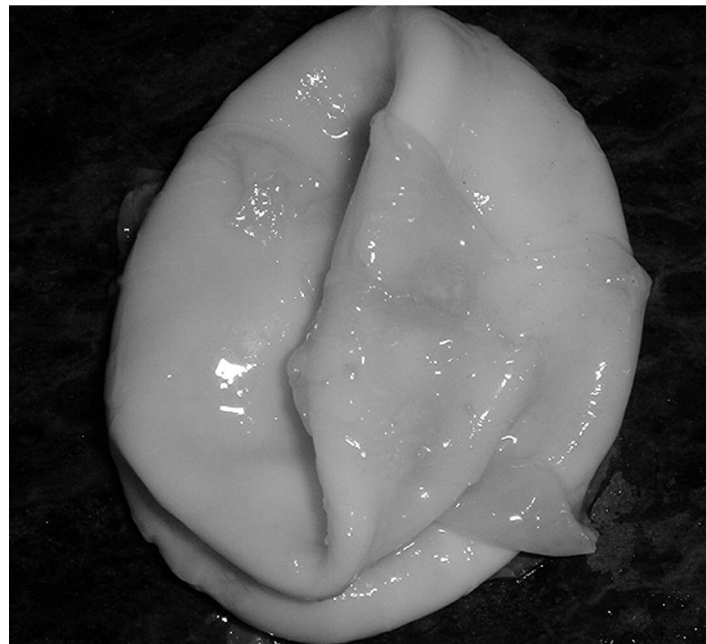


Figure 4. Gross photograph of the laminated membrane retrieved from the cystic lesion.

health problem: introduction. *World J Surg.* 2001;25(1):1-3.

2. Nagpal V, Kohli K, Chowdhary A, et al. Breast lump as a presentation of a hydatid disease. *Trop Doct.* 2006;36(1):57-8.

3. Tutar N, Cakir B, Geyik E, et al. Hydatid cysts in breast: mammography and ultrasound findings. *Br J Radiol.* 2006;79(946):e114-6.

4. Erkan N, Hacıyanlı M, Yildirim, et al. A case report of the unusual presence of hydatid disease in the pancreas and breast. *JOP.* 2004;10:368-72.

5. Epstein NA. Hydatid cyst of the breast: diagnosis using cytological techniques. *Acta Cytol.* 1969;13:420-1.

6. Bengisun U, Ozaslan C, Kutlay J, et al. Primary hydatid cyst of the breast. Case report. *Eur J Surg.* 1993;159(9):503-4.

7. Jacobson ES. A case of secondary echinococcosis diagnosed by cytologic examination of pleural fluid and needle biopsy of pleura. *Acta Cytol.* 1973;17:76-9.

8. Charfi S, Khabir A, Ayadi L, et al. Mammary hydatid cyst diagnosed by fine needle aspiration. *Rev Med Interne.* 2007;28(5):336-8. Epub 2007 Jan 26.

9. Saimot AG. Medical treatment of liver hydatidosis. *World J Surg.* 2001;25:15-20.

10. Biava MF, Dao A, Fortier B. Laboratory diagnosis of cystic hydatid disease. *World J Surg.* 2001;25:10-4.